

ARTICLE

Congenital external auditory canal atresia and methods of rehabilitation

Ádám Perényi*, Attila Nagy, József Géza Kiss, László Rovó

Department of Otorhinolaryngology, Head and Neck Surgery, Albert Szent-Györgyi Clinical Center, University of Szeged, Hungary

ABSTRACT Congenital external auditory canal atresia is a disorder with a prevalence of one in 10 000-20 000 live births and is bilateral in one third of the patients. With a conductive hearing loss of 60 dB, even unilateral atresia restricts hearing related social skills. The degree of middle ear deformity may make reconstruction surgery impossible or too hazardous, thus bone-conduction hearing aids have become the first-line therapy. Children with unilateral cartilaginous and bony external auditory canal atresia were enrolled. High-resolution computed tomography with three dimensional reconstructions were made. Reconstruction surgery from retroauricular approach comprised maximal enlargement of the tympanic and mastoid cavities and their closure with adapted conchal cartilage. Hearing improvement reached the level above the social threshold. The auditory canal remained stable and widely patent and facial nerve function was unremarkable. The authors highlight that surgical reconstruction of the external auditory canal is possible in selected cases. The procedure is safe and effective with a reasonably short surgical time, if it is supported by deep anatomical knowledge, careful preoperative imaging and intraoperative facial nerve monitoring. Stable audiological benefits improve patients' satisfaction and quality of life. If reconstruction surgery is not possible, bone-conduction hearing aids are beneficial.

Acta Biol Szeged 59(Suppl.3):341-343 (2015)

KEY WORDS

bone-conduction hearing aids
external auditory canal atresia
reconstruction
3D imaging

Introduction

Congenital external auditory canal atresia is a disorder with a prevalence of one in 10 000-20 000 live births and is bilateral in one third of the patients. It is characterized by complete or incomplete bony atresia of the external auditory canal. Being a complex developmental disorder of the temporal bone, it can be associated with malformations (*e.g.*, malformation of the ossicles, hypoplasia of the tympanic and mastoid cavities, malformation of the temporomandibular joint, and microtia) (Jahrsdoerfer 1978). The facial nerve may be variable in structure and position (Tasar et al. 2007). Conductive hearing loss of 60 dB is typical. If unilateral, hearing and speech development is usually normal or near normal. In bilateral atresia, speech development is compromised and this condition requires therapy in an early age.

A preferable therapy is surgical repair of the missing external auditory canal. Due to the developmental degree of the mastoid and tympanic cavities, the absence of anatomical

landmarks, the variety in the shape and position of the anatomical structures, abnormal position of the facial nerve and structural deformities of the ossicles, reconstruction surgery is difficult and hazardous (Kesser 2010). Because of the good cost-benefit ratio, bone-conduction hearing aids have become the first-line therapy in very low age and in those cases in which the surgical outcome is doubtful. Bone-conduction hearing aids include non-implantable and implantable, percutaneous and transcutaneous, active or passive systems.

Surgical repair of the missing external auditory canal has some fundamental requirements. When planning surgery one has to pay attention to the position of the facial nerve and the tympanic tegmen, the anatomy of ossicles (stapes and malleus-incus complex), the pneumatisation and spatial development of the tympanic and mastoid cavities, the development of the oval and round windows (Kesser 2010). Jahrsdoerfer et al. (1992) published a scoring system which helps to predict postoperative hearing outcome and assist in determining surgical candidacy (Shonka et al. 2008). During the removal of excess bone with a burr, the normal anatomical landmarks are missing, thus injury to the facial nerve is a real danger. Even experienced surgeons need long time to visualize and avoid the structures at risks. Meticulous preoperative assessment of the shape and position of the facial

Submitted June 15, 2015; Accepted July 30, 2015

*Corresponding author. E-mail: perenyi.adam@med.szote.u-szeged.hu

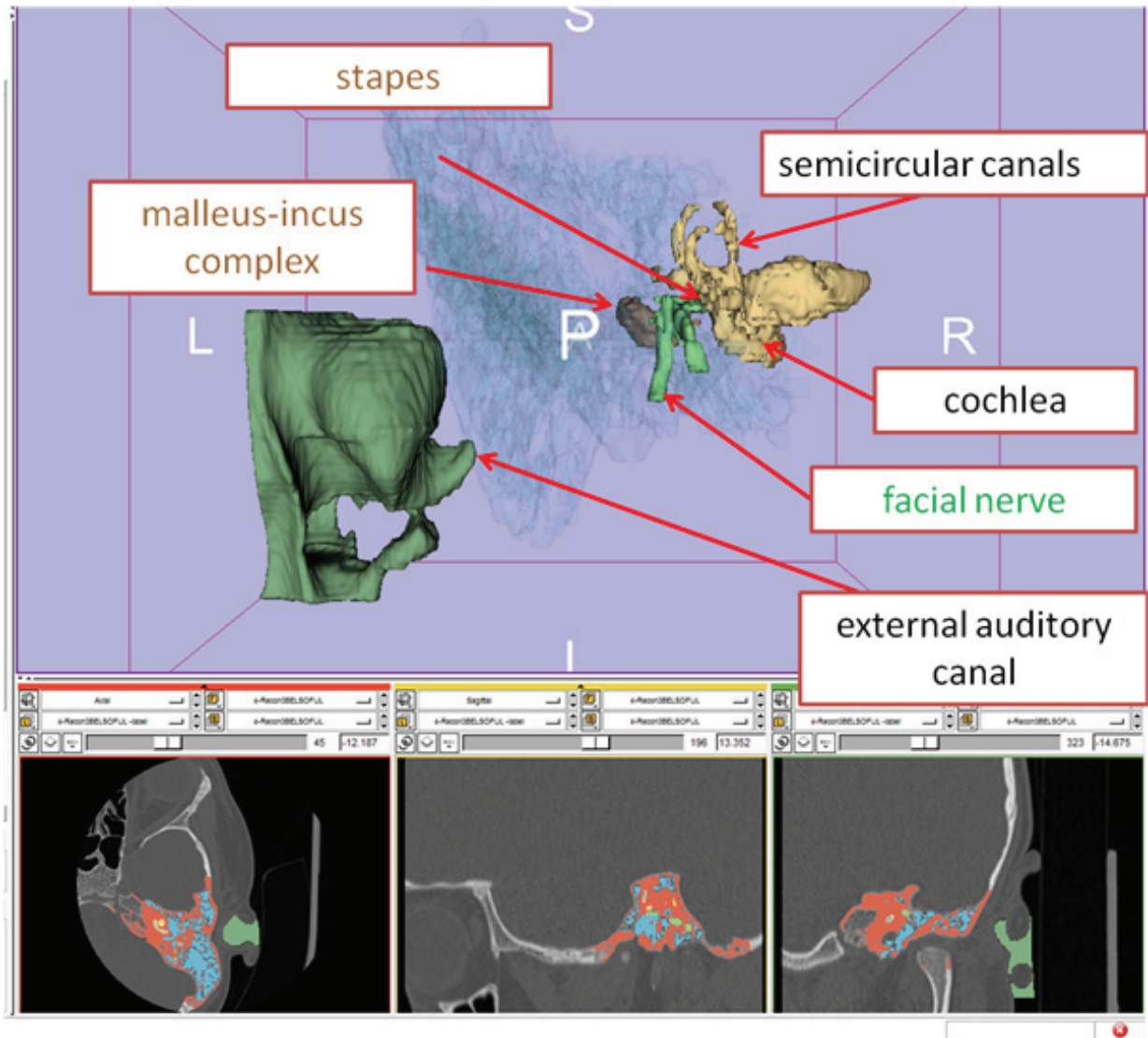


Figure 1. Three dimensional CT reconstruction of the external, middle, and inner ear of the ear with external auditory canal atresia. 3D Slicer 4.3.

nerve with imaging diagnostics is crucial, because the facial nerve has been reported to be abnormal in position in 25 to 52% of atresia patients, its bony canal can be dehiscent and abnormal bifurcation has also been seen (Chang et al. 1994; Jahrsdoerfer and Lambert 1998).

Materials and Methods

Two 6-year-old subjects with unilateral congenital external auditory canal atresia have been enrolled. Apart from minor anomalies of the pinna, the external ears were unremark-

able. Unilateral conductive type hearing loss of 60 dB with normal contralateral hearing level was seen in both subjects. Both subjects were trained by speech therapists due to minor articulation issues.

In order to make successful surgical planning, reconstruction images were made, in that the preoperative CT reconstructions were generated with 3D Slicer (a free and open-source imaging software from high resolution, non-enhanced axial CT images (DICOM) of the head with ear protocol. 3D Slicer was used in visualizing anatomical structures by three-dimensional reconstructions of the trachea and this was successfully applied in the surgical reconstruction of a critical case (Furák et al. 2011; Perényi et al. 2014).

By showing the structures of the external, middle, and inner ear we aimed to provide the ear surgeon with inevitable information about the anatomical landmarks, the absolute and relative three-dimensional anatomy of the anatomical structures with focus on the facial nerve and the ossicles (Fig. 1) (Perényi et al. 2014).

Surgical repair from retroauricular approach comprised maximal enlargement of the tympanic and mastoid cavities and their closure with adapted conchal cartilage. Hearing improvement reached the level above the social threshold. The auditory canal remained stable and widely patent and facial nerve function was preserved. Stable audiological benefits improved the patients' quality of life.

Results

Both patients had congenital external auditory canal atresia. Reconstruction surgery was predicted to be effective based on the Jahrsdoerfer grading system (Jahrsdoerfer et al. 1992). Preoperative CT reconstructions demonstrated slight hypoplasia of the mastoid cavities in both cases. The mastoid and tympanic cavities were air-containing. Bony atresia was found in both cases. The tympanic membrane and handle of the malleus were absent, but the rest of the ossicular chain, although malformed (malleus-incus complex and stapes) were present. The inner ear was unremarkable and the round window was open. The position of the facial nerve was near normal in both cases, although bifurcation in the mastoid section was seen in case 2. The position of tympanic section of the facial nerve (slightly but always medial to the malleus-incus complex) allowed for straightforward and quick surgical preparation until the malleus-incus complex was reached without putting the facial nerve into risk. The latter was assisted with a facial nerve monitoring system.

Discussion

Careful selection of candidates for surgery is paramount. In the authors' opinion when considering surgical repair of external auditory canal atresia it is inevitable to have high quality, high resolution CT scans of the ears, which enable accurate

reconstructions in each conventional (axial, coronal, and sagittal) and any non-conventional plane. Three-dimensional reconstructions give further important information about the spatial relationship of the anatomical structures at risk. By applying the appropriate criteria (*e.g.*, the Jahrsdoerfer grading system) together with thorough imaging the result of surgery can be predicted and an individual surgical plan can be set up. This method renders straightforward visual information to the surgeon, thus, based on the preoperative plans, the surgical procedure can be conducted quickly and with low risk.

References

- Chang SO, Min YG, Kim CS, Koh TY (1994) Surgical management of congenital aural atresia. *Laryngoscope* 104:606-611.
- Furák J, Szakács L, Nagy A, Rovó L (2011) Multiple costal cartilage graft reconstruction for the treatment of a full-length laryngotracheal stenosis after an inhalation burn. *Interact Cardiovasc Thorac Surg* 13:453-455.
- Jahrsdoerfer RA, Lambert PR (1998) Facial nerve injury in congenital aural atresia surgery. *Am J Otol* 19:283-287.
- Jahrsdoerfer RA, Yeakley JW, Aguilar EA, Cole RR, Gray LC (1992) Grading system for the selection of patients with congenital aural atresia. *Am J Otol* 13:6-12.
- Jahrsdoerfer RA (1978) Congenital atresia of the ear. *Laryngoscope* 88:1-48.
- Kesser BW (2010) Repair of congenital aural atresia. *Oper Techn Otolaryngol* 21:278-286.
- Perényi A, Nagy A, Kiss JG, Rovó L (2014) Képi rekonstrukciók szerepe fülműtétekben, fülfeljélődési rendellenesség esetében. In Bari F, Almási L, eds., *Orvosi Informatika 2014: A XXVII Neumann Kollokvium Konferenciakiadványa*, 127-130 [*in Hungarian*].
- Shonka DC, Livingston WJ, Kesser BW (2008) The Jahrsdoerfer grading scale in surgery to repair congenital aural atresia. *Arch Otolaryngol Head Neck Surg* 134:873-877.
- Tasar M, Yetiser S, Yildirim D, Bozlar U, Tasar MA, Saglam M, Ugurel MS, Battal B, Ucoz T (2007) Preoperative evaluation of the congenital aural atresia on computed tomography; an analysis of the severity of the deformity of the middle ear and mastoid. *Eur J Radiol* 62:97-105.

