

ARTICLE

Developmental anomalies and other pathological lesions of the sternum in a medieval osteological sample

Gyula L. Farkas^{1*}, László Józsa², László Paja¹

¹Department of Anthropology, University of Szeged, Szeged, Hungary, ² Department of Morphology, National Institute of Traumatology, Budapest, Hungary

ABSTRACT We cannot often read about the developmental anomalies of the sternum in paleopathological literature (Brothwell 1965; Tóth and Buda 2001); medical publications on anomalies resulting in chest deformity based on recent population are also rare (Keszler and Szabó 1996). Fractures and inflammation of the sternum are fairly infrequent, and the symptoms of porotic hyperostosis caused by increased red blood cell production are seldom detected in osteological samples. Some developmental anomalies (e. g. sternum fenestratum, alterations of the xiphoid process) do not influence the function or physiological form of the chest, while others may change the shape and diameter of the chest causing difficulties in breathing and in heart function. Some genetic diseases, through the malfunction of the production of the connecting tissues' basic substantia and fibres, necessarily entail changes in the shape of the sternum. In individuals suffering from Marfan syndrome, sternum excavatum, while in individuals suffering from Hurler- and Morquio-syndrome (and other mucopolysaccharidosis cases), pectus gallinaceum can be observed. Other sternum anomalies resulting from non-genetic factors also seem to run in the family, though how they are inherited is not yet known. An anomaly called synchondrosis sternii develops during postnatal life, and means that the originally cartilaginous sternebra do not become ossified, there remain synchondrosis between the parts even through the whole lifetime. This, however, does not cause abnormal chest movement. In some cases, the fracture of the sternum may lead to serious respiratory disfunction, and the healing of these injuries without any surgical intervention is not guaranteed. The development of pseudo-articulations may also cause abnormal chest movement. Osteomyelitis spreading to other organs may prove to be dangerous, even fatal.

KEY WORDS

14-15th century
paleopathological finds
sternum
developmental anomalies

Acta Biol Szeged 48(1-4):39-42 (2004)

It was in 1966, when 103 graves were dug out by archaeologist Mihály Kőhegyi at the site of Bátmonostor-Pusztafalu (15 km from Baja southward, Southern Hungary; Kőhegyi 1967). Later, between 1977 and 1986, Piroška Biczó continued the excavation: 2543 further graves were excavated. In Biczó's opinion, the cemetery dates back to the 14th-15th century, and 80% of the graves have been excavated (Biczó 1978-1986). We have to note, however, that this is the biggest medieval cemetery found in Hungary so far.

Materials and Methods

The age determination of the infant and adolescent individuals was carried out on the basis of the diaphyseal length of long bones (Stloukal and Hanáková 1978), the sequence of tooth formation and eruption (Ubekaler 1978) and the ossification of the epiphyses based on X-ray examination (Schinz et al 1952). The age determination of adults was based on the method of Nemeskéri et al. (1960).

Sex determination of the skeletons was carried out on the

basis of 24 metric and non-metric morphological characteristics of the skull and post-cranial bones showing sexual differences, which was possible only in case of adult and some juvenile individuals (Éry et al. 1963). Anatomic variations were detected in a large number of cases (827), while further 868 cases of other pathological lesions were observed (often several different kinds in one individual). The above shows the finds' anthropological importance. During the paleopathological analysis the sternal length and its possible alterations were measured in millimetres. In case of sternums of irregular shape, the angular deviation was recorded, the angle between the two distal parts was measured.

Anthropological data

3782 individuals' skeletal remains were found in 2646 graves; more than one individual was found in 444 graves. A considerable part of skeletons (1510 cases, 39.9%) belongs to the Infancia I and II categories, while the Juvenis age category includes 153 skeletons (4.05 %). Among skeletal remains of adults (>21 years of age; Adultus, Maturus and Senium categories) 1342 males (35.48%) were determined, while in

Accepted Jan 29, 2004

*Corresponding author. E-mail: farlgy@bio.u-szeged.hu



Figure 1. Bifurcation of the xiphoid process (grave 2114, Mat., male).

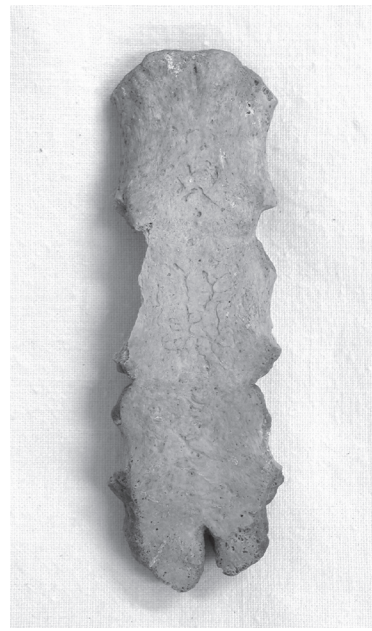

Figure 2. Sternum bifidum (grave 1774, adult, male).

719 cases characteristics of females can be seen. During the excavation, as a result of the careful rescue, the remains of 39 fetuses were rescued (included in the Infantia category). Unfortunately, in case of 123 (3.18%) skeletons, neither the sex, nor the age at death was determinable.

Results

Developmental alterations

Anomalies were detected in 40 breast-bones, among which the co-existence of two alterations can be seen in only two cases, in the rest of cases only one lesion was observed. In

four cases the change of the xiphoid process was found, in one of them the two branches of the splitted process were at right angles. In two further cases the distal two-third of the breastbone showed a V-shaped bifurcation, the branches closed at an angle of 35 and 60 degrees, respectively (Fig. 1). Sternum bifidum was determined in five cases (Fig. 2). Synchrondrosis sternii (incomplete ossification of the sternum) was recorded in 7 cases. Other anomalies in the shape of the sternum (wedge-shaped or asymmetrical bone) were found in two cases (Table 1).

The large number of sternum gallinaceum cases must be noted. The anomaly both occurred in small children (Infantia

Table 1. Developmental anomalies of the sternum at the finds from Bátmonostor.

Grave No.	Age at death	Sex	Grave No.	Age at death	Sex
	Fenestratio			Synchrondrosis	
814	Juv.	male	182	Mat.	female
1107	Sen.	male	259	Mat.	female
1456	Sen.	male	355	Mat.	female
1740	Mat.	female	747	Mat.	female
1992	Ad.	female	1278	Ad.-Mat.	male
2126.	Sen.	male	1383	Mat.	male
2148.	Juv.	?	2431	Mat.	male
2382	Ad.	male		Sternum bifidum	
2551.	Mat.-Sen.	female	1278	Ad.-Mat.	male
2557	Mat.-Sen.	male	1774	adult	male
B/XXIII.	?	?	1814	Ad.	male
	Anomalies of the xiphoid process		2518	Mat.	male
767	Ad.	male	2567	Inf. II	?
1217	Ad.	male		Other morphological anomalies	
1941	Mat.	male	898	Mat.	female
2114	Mat.	male	137/b	?	?

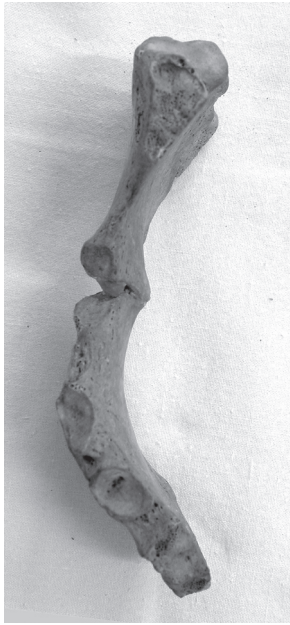


Figure 3. Pectus gallinaceum (grave 1414, Mat., female).

I) and old individuals, mostly affected males (as all other anomalies). The deviation ranged from 10 degrees to 46. (Table 2, Fig. 3).

Table 2. The occurrence of pectus gallinaceum.

Grave No.	Age at death	Sex	Angle of deviation	Sternal length (mm)	Other pathological alterations
767	Ad.	male	30°	-	Anomaly of xiphoid process
858	adult	male	46°	80	
1028	?	?	38°	130	
1107	Sen.	male	30°	140	
1383	Mat.	male	10°	130	
1414	Mat.	female	32°	140	
1473/a	Inf.I.	?	-	-	
2125	Mat.	female	39°	160	
2264	Ad.-Mat.	female	28°	150	
2372	Mat.	male	20°	160	
2395/a	adult	male	12°	170	Hyperostosis porotica
2567	Inf.II.	?	14°	80	
B/X.	?	?	20°	170	

Table 3. The pathological alterations of the sternum.

Grave No.	Age at death	Sex	Symptoms
1435	Inf.I.	?	Osteomyelitis pur.sterni
2607	Sen.	male	Ostitis et periostitis sterni
2148	Juv.	?	Fractura sterni
2330	Ad.	male	Fractura sterni
1440	Mat.	male	Fractura sterni
747	Mat.-Sen.	female	Periostitis sterni
1278	Ad.-Mat.	male	Periostitis sterni
1480/a	Ad.-Mat.	male	Periostitis sterni
2645	Sen.	male	Periostitis sterni
1134/a	Mat.	male	Arthritis pur.sternoclav.
1305	Sen.	male	Arthritis pur.sternoclav
814	Juv.	male	Hyperostosis porotica
2395/a	adult	male	Hyperostosis porotica

Other pathological anomalies

Other pathological anomalies were detected on 13 sternums. Osteomyelitis of the sternum in two cases, periostitis in four cases was recorded. Three sternums were broken, all partially ossified. Two cases of purulent arthritis of the sternoclavicular joint were observed, which went together with the fracture of the clavicle and osteomyelitis. On two sternums traces of porotic hyperostosis can be seen. (Table 3).

Discussion

The body of the sternum and the xiphoid process are originally formed of cartilaginous tissue, the fusion and ossification of the bone becomes complete in postnatal life. Sternum fenestratum indicates abnormal ossification (Ashley 1956).

Perforated sternum is the most common abnormality (Tóth et al. 2001), but bears no pathological significance. The mechanism of the formation of pectus gallinaceum is not yet understood. In such cases the length and shape of the ribs are affected. Pectus gallinaceum often occurs with serious curvature of the spine (kyphoscoliosis), though we did not find any such cases.

Although we seldom had the opportunity to examine all the bones of the chest, it is supposed that there was no major chest deformity in this sample. Most individuals suffering from pectus gallinaceum were adults at death (Adultus or